

## DEVELOPMENT DENTAL ANOMALIES IN A GROUP OF SCHOOL CHILDREN – A PRELIMINARY STUDY

Dan Emil GEORGESCU, Rodica LUCA and Elisa Mădălina CHIRCA

“Carol Davila” University of Medicine and Pharmacy, Bucharest, Romania

Corresponding author: Dan Emil GEORGESCU, E-mail: [georgescudanemil@yahoo.com](mailto:georgescudanemil@yahoo.com)

Accepted November 16, 2015

*The present study purpose was to assess the frequency of development anomalies of teeth and soft tissue in the anterior region, of a school children from Bucharest. Material and methods: 226 children from two secondary schools, aged between 5 and 8 years were included. (1) Cross-sectional clinical study. (2) Pupils were examined in the school dental office. (3) The presence of dental development anomalies or of other types was recorded. (4) The frequency of developmental anomalies was determined. 4.87% of the examined school children had oral developmental anomalies: 2 dental size anomalies (0.44%) - one fusion and one gemination and 9 abnormal maxillary frenum attachment (3.98%). (3) Dental anomalies were found in front teeth, in both dentition. (4) Diastema was found in permanent dentition, between the two upper central incisors. The evaluated age group had a low frequency for front teeth dental development anomalies. Follow up of all children is necessary until the eruption of all permanent teeth. Children with diastema require monitorization in order to observe its evolution and to intervene if necessary.*

**Keywords:** developmental anomalies, fusion, gemination, diastema

### INTRODUCTION

When talking about oral examination in children, we do not refer only to the teeth examination, caries discovery and prevention or to the talks with the parents regarding the child's diet or dental hygiene, but we also refer to the examination of the soft and hard structures of the oral cavity<sup>1</sup>.

Oral developmental anomalies can be found both at the teeth and the soft tissue. Dental developmental anomalies appear as a result of disruption in the odontogenesis process by the action of certain disruptive factors.

The disruptive factors can be genetic factors or environmental factors or even combinations of these factors. Dental developmental anomalies can be anomalies of **number, size, shape, structure, or color**<sup>2</sup>. Amongst these dental developmental anomalies, shape anomalies like *gemination* and *fusion* can be mentioned. Gemination appears as a result of total or partial tooth germ splitting. The coronary division can be total or partial. Within the total division two dental crowns result, which have one root and one channel. Within the partial division, the result will consist of a sole dental crown which has an incisal splitting.<sup>2</sup>

Fusion appears as a result of coalescence of two or more separated tooth germs. The dental fusion can be complete or incomplete.

Within the complete fusion, it results a single over-sized crown, with one pulp chamber and one radicular channel.

The incomplete fusion leads to the appearance of two pulp chambers and two radicular channels, united by means of the dentin.

Because sometimes it is difficult to make a clinical differentiation between gemination and fusion, they can be described, regardless of type, as double teeth.

These two types of anomalies can be found in both dentitions but are prevalent in primary one, with incisors being more frequently affected<sup>2</sup>.

Various studies on the prevalence of such anomalies revealed quite low values, but varies from country to country. Thus, Hagiwara and co, found in Japanese population, that the prevalence of double teeth is 0.05% of 9584 participants<sup>3</sup>.

Lochib, Wangrimongkol and Hamasha and col. found in Saudi Arabian, Thai, respectively Jordanian population, a prevalence of 0.4% of double teeth (fusion and gemination)<sup>4-6</sup>. Instead, Tesa and Lukacs found in western India population that the prevalence rate of double primary teeth is 1.5%<sup>7</sup>. And Kapdan and col. found that the prevalence of gemination and fusion in primary dentition of Turkish children is 1.3%<sup>8</sup>. This prevalence is also reported by Kramer for Brazilian children<sup>9</sup>.

Separately reported, Hamasha and col. found that the prevalence of gemination is 0.22% and the prevalence of fusion is 0.19%<sup>6</sup>. For fusion teeth, Ezoddini and col. found almost the same value: (0.2%) for the Iranian population<sup>10</sup>.

Among soft tissue anomalies, an abnormal maxillary frenum attachment can be mentioned. Abnormal frenum attachment can contribute to the appearance of some anomalies of the dental-maxillary apparatus. Which is why the early interception can have beneficial effects in preventing the establishment of such anomalies during the period of mixed teeth or in adult teeth. An abnormal maxillary frenum attachment may lead to the appearance of a diastema vera (true diastema).

The diastema appears as a physiological space during the primary and mixed dentition in children, space which, most of the times, closes when the upper canine teeth appear on the arcade. The issues start to appear when the diastema does not close<sup>11</sup>

A proof that the diastema is most of the times a physiological stage, is the fact that the closure of the diastema follows the eruption pattern of the lateral permanent canines and incisors.

Due to this process exactly, the prevalence of diastema is higher at small ages and starts to decrease around the age of 9-15 years old<sup>11</sup>

Assuming that, even if this developmental anomalies are rare, it is known that they can produce at least local disorders with influence on the functionalities of the dental-maxillary level and we want to find out which is their frequency in the frontal area, because in Romania the studies on this topic are scarce.

The aim of the study was to assess the frequency of development anomalies of teeth and soft tissue in the anterior region.

## MATERIAL AND METHODS

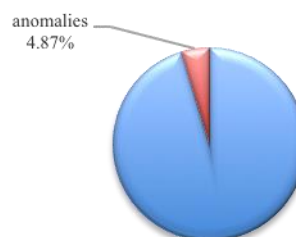
A cross-sectional study was performed on a group of children, pupils of a secondary school from Bucharest. The educational institutions were chosen because they had a dentist's office, which provides optimum conditions to examine the patients. Pupils from grades 0 and 1 were included in the study, who cooperated and whose parents agreed to include the children in the study. School children from higher grades, non-cooperating children and children whose parents did not agree to include them in the study were excluded from the study.

The clinical exam of the children was performed by a single dentist (DE-G). No radiological examination was performed. The presence of dental developmental anomalies or of other types of oral anomalies was recorded in individual sheets. The data was centralised and the frequency of oral developmental anomalies was calculated. Statistical analysis was performed in Microsoft Excel for Mac 2011.

## RESULTS AND DISCUSSIONS

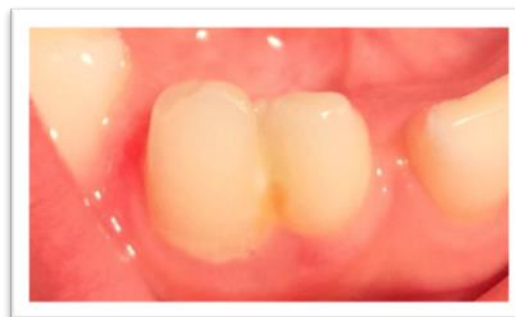226 pupils (107 girls, 119 boys), with ages between 5 years old and 8 years and 4 months old (mean age = 6 years and 6 months), were examined. 125 pupils were examined in the first school, and 101 in the second school.

4.87% (n=11) of the examined school children had oral developmental anomalies (Figure 1)

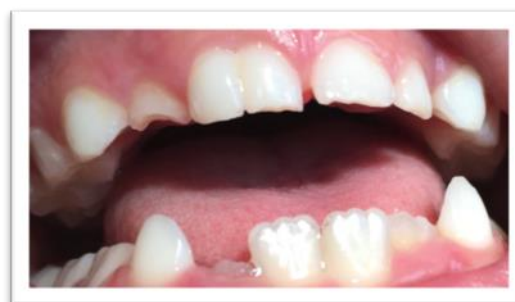

**Figure 1.** Percentage of schoolchildren with developmental anomalies

In two children (0.44% of the total of pupils examined), dental developmental anomalies were clinically found: one fusion between lower primary lateral incisor and canin – 8.2 and 8.3 (Figure 2) and one gemination of upper right permanent central incisor – 1.1. (Figure 3).

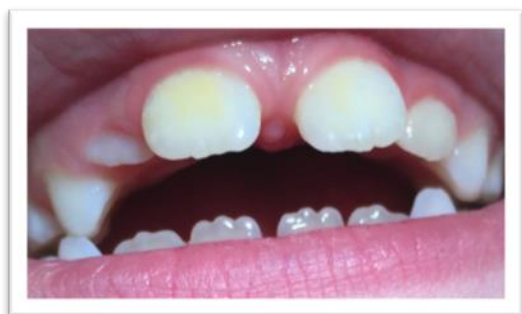

**Figure 2.** Fused teeth 8.2 and 8.3



**Figure 3.** Gemination of 1.1

In nine children (3.98% of the total of pupils examined), diastemas were observed. Diastema was present at 7 girls (6.54% of the girls) and at 2 boys (1.68% of the boys). The mean age of children with diastema was 7 years and 3 months. Diastema was found in permanent dentition, between the two upper central incisors (Figure 4).



**Figure 4.** Diastema between the two upper permanent central incisors

Dental anomalies were found in front teeth, in both dentition and were determined only in shape dental anomalies. One fusion and one gemination were found, their frequency representing 0.4% of the total of 226 pupils examined. The frequency determined in this study fall under the frequencies reported in the specialty literature for this type of dental developmental anomalies. Our values are similar to those reported by Lochib, Wangrimongkol and Hamasha and col.<sup>4-6</sup> and close to that reported by Sekerci and col. that found a frequency of 0.38% in their study at a Turkish university<sup>12</sup>.

Hattab and Temilola and col. have also shown that the fusion and the gemination have a prevalence between 0.1 and 0.9% in white children<sup>13, 14</sup>. On the other side, the frequency determined in our study is lower than the one reported by Cameron and Widmer<sup>15</sup>, who reported the presence of double teeth in primary dentition at 2.5% of the children examined.

With regard to the topography of the two form anomalies, the fusion is more often found in mandibular primary incisors, and the gemination in incisors and maxillary canines<sup>13</sup>.

The fusion found in our study is between teeth 8.2 and 8.3, which coincides with the data from the specialty literature<sup>7</sup>. With regard to the gemination, the only case we found was in a maxillary permanent incisor (tooth 1.1), while a higher frequency in the primary teeth is reported in the specialty literature.<sup>2</sup>

The presence of the diastema, found in our study, is not an unusual situation for the age group of the children examined, but the evolution in time should be followed.

## CONCLUSIONS

The evaluated age group had a low frequency for front teeth dental development anomalies. Follow up of all children is necessary until the eruption of all permanent teeth. Children with diastema require monitorization in order to observe its evolution and to intervene if necessary.

**Acknowledgement** This work was cofinanced from the European Social Fund through Sectoral Operational Programme - Human Resources Development 2007-2013, project number POSDRU/1871.5/S/155605, entitled "Doctoral programs at the forefront of research excellence in priority domains: health, materials, products and innovative processes", Beneficiary – University of Petroșani.

## REFERENCES

1. Kotlow L.A. Oral diagnosis of abnormal frenum attachments in neonates and infants: evaluation and treatment of the maxillary frenum using the erbium: YAG Laser. The journal of the Academy of Laser Dentistry. 2005;XIII(1):26-28.
2. Luca R. Pedodontie. Vol.3. Editura CERMA PRINT. București. 2013:92-96.
3. Hagiwara Y, Uehara T, Narita T, Tsutsumi H, Nakabayashi S, Araki M. Prevalence and distribution of anomalies of permanent dentition in 9584 Japanese high school students. Odontology. 2015; 26;
4. Lochib S, Indushekar KR, Saraf BG, Sheoran N, Sardana D. Occlusal characteristics and prevalence of associated dental anomalies in the primary dentition. J Epidemiol Glob Health. 2015; 5(2):151–7.
5. Wangrimongkol T, Manosudprasit M, Pisek P, Chittiwatanapong N. Prevalence and types of dental anomaly in a Thai non-syndromic oral cleft sample. J Med Assoc Thai. 2013; 96 Suppl 4:S25–35.
6. Hamasha AA-H, Al-Khateeb T. Prevalence of fused and geminated teeth in Jordanian adults. Quintessence Int. 2004; 35(7):556–9.
7. Tasa GL, Lukacs JR. The prevalence and expression of primary double teeth in western India. ASDC J Dent Child. 2001; 68(3):196–200.
8. Kapdan A, Kustarci A, Buldur B, Arslan D, Kapdan A. Dental anomalies in the primary dentition of Turkish children. European journal of dentistry. 2012; 6(2):178.
9. Kramer PF, Feldens CA, Ferreira H, Spiguel MH, Feldens EG. Dental anomalies and associated factors in 2- to 5-year-old Brazilian children. Int J Paediatr Dent 2008; 18(6): 434-440.
10. Ezoddini AF, Sheikha MH, Ahmadi H. Prevalence of dental developmental anomalies: a radiographic study. Community Dent Health. 2007; 24(3):140–4.
11. Huang W-J, Creath CJ. The midline diastema: a review of its etiology and treatment. Pediatric dentistry.1995; 17:171–179.
12. Sekerci AE, Sisman Y, Ekizer A, Sahman H, Gumus H, Aydinbelge M. Prevalence of double (fused/geminated) primary teeth in Turkey – A study. Pakistan Oral&Dental Journal 2011; 31(1): 7-13.
13. Hattab F. Double talon cusps on supernumerary tooth fused to maxillary central incisor: review of literature and report of case. Journal of Clinical and Experimental Dentistry. 2014:e400–7.
14. Temilola DO, Folayan MO, Fatusi O, Chukwumah NM, Onyejaka N, Oziegbe E, et al. The prevalence, pattern and clinical presentation of developmental dental hard-tissue anomalies in children with primary and mix dentition from Ile-Ife, Nigeria. BMC oral health. 2014;14(1):125.
15. Cameron AC, Widmer R. Handbook of Pediatric Dentistry. 4<sup>th</sup> Edition. Mosby. Elsevier 2013: 289-292.