

BORDERLINE LESIONS OF UTERINE CERVIX PROGRESSION, REGRESSION, TREATMENT: GUIDELINES VS PRACTICE

Alina DATCU¹, Radu VLADAREANU², Bogdan BOTEZATU¹ and Ioan BOLEAC¹

¹ "Panait Sirbu" University Hospital, Obstetrics and Gynecology Department, Bucharest, Romania

² "Elias" University Hospital, Obstetrics and Gynecology Department, Bucharest, Romania

Corresponding author: Alina DATCU, E-mail alina.m.datcu@gmail.com

Accepted November 16, 2015

Knowing that latest guidelines recommended higher screening intervals for cervical cancer, up to 3 or 5 years and according to European reports, Romania was the leading country for incidence and mortality in cervical cancer, our study objectives were to determine the incidence of cytological borderline abnormalities defined as atypical squamous cells of undetermined significance (ASCUS) and atypical glandular cells (AGCs), to describe the associated pathologic findings so we can be able to balance needed and unnecessary treatment and to determine the frequency of follow-up screenings. Do we need new follow-up criteria in these cases, knowing the high incidence in cervical cancer for our country?

Keywords: cervical cancer, ASC-US, AGC, borderline, HPV

INTRODUCTION

The relationship between human papillomavirus infection and cervical cancer is well known. This virus infects only keratinocytes of the skin and mucous membranes. Most HPV infections are subclinical; in some people subclinical infections will become clinical and may cause warts or premalignant lesions that will drive to cancers of the cervix, vulva or vagina.

Researchers have identified over 150 types of HPV, more than 40 of which are typically transmitted through sexual contact and infect the anogenital region, and divided in two major classes: low risk and high risk¹. The most common etiological cause of genital warts is HPV-LR types 6 and 11. HPV-HR 16 and 18 are responsible for persistent infection, may progress to precancerous lesions and invasive cancer; they are known to cause around 70% of cervical cancer cases^{2,3}.

70% of clinical HPV infections in healthy young adults may regress to subclinical forms in one year and 90% in two years. However, when the subclinical infection persists — in 5% to 10% of infected women — there is high risk of developing precancerous lesions of the cervix which can progress to invasive cancer. Progression from subclinical to clinical infection may take years, providing opportunities for detection and treatment of pre-cancerous lesions⁴.

A Pap smear is considered abnormal when the laboratory interprets the cellular changes to be different from those

normally seen on a healthy cervix. ASC-US and AGC are considered borderline changes.

ASC-US (atypical squamous cells of undetermined significance) is the most common cytological abnormality. 2013 ASCCP (American Society for Colposcopy and Cervical Pathology)⁶. Papanicolau Smear Guidelines indicate that for women with ASC-US cytology, reflex HPV testing is preferred. For women with HPV-negative ASC-US (reflex HPV testing or co-testing), is recommended to repeat co-testing at 3 years. For women with HPV-positive ASC-US, whether from reflex HPV testing or co-testing, colposcopy is recommended. When colposcopy does not identify CIN in women with HPV-positive ASC-US, co-testing at 12 months is recommended. If the co-test is HPV negative and cytology negative, return for age-appropriate testing in 3 years is recommended. If all tests are negative at that time, routine screening is recommended. After colposcopy HPV testing is recommended at intervals of more than 12 months. For women with ASC-US cytology and no HPV result, repeated cytology at 1 year is acceptable. If the result is ASC-US or worse, colposcopy is recommended; if the result is negative, return to cytology testing at 3-year intervals is recommended.

AGC (Atypical Glandular cells) is associated with higher rates of abnormalities and thus, in the absence of an abnormality found by colposcopy, endocervical curettage should be done in all women, and endometrial sampling should be performed in women over 35 years of age or who

have a history of abnormal bleeding, including anovulation⁶. However, with AGC cytology and the absence of an identified lesion, women are still at risk of developing a lesion. In this situation, follow-up assessment every 6 months for 2 years includes repeat cytology testing, colposcopy, and endocervical curettage. If HR-HPV testing is available and was done at the initial colposcopy visit, women who test negative for HR-HPV may have repeat assessment with colposcopy, cytology testing, endocervical curettage, and HR-HPV testing at 12 months. If a lesion is identified, treatment is in accordance with the guideline specific to the type of lesion. If all follow-up is negative after 2 years, routine cytologic testing may be resumed.

MATERIAL AND METHODS

All patients with Papanicolaou borderline smear ASCUS type were monitored with both colposcopy and HPV genotype detection, while patients with Papanicolaou smears with atypical glandular cells (AGCs) were monitored with colposcopy and endocervical-endometrial biopsy. Follow-up screening interval for abnormal PAP smear was: 6 months, 1 year or 2 years.

RESULTS AND DISCUSSIONS

We examine, in a prospective cohort study, 57 patients with new smears interpreted as borderline. Women between 21 years of age to 65 years were included, with following distribution in Figure 1.

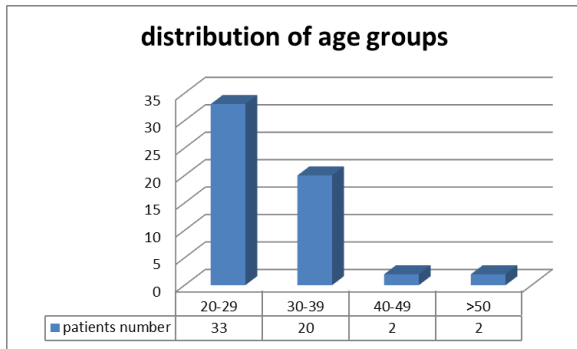


Figure 1 The highest incidence of borderline results between 20-29 years of age, with lowest incidence above 40 years

Above the age of 40 we noted a significant decreasing incidence of borderline Pap smear. We included women of reproductive age and menopausal. All women at menopause received an ASC-US result, while in women of reproductive age we found out both ASC-US and AGC. Only 7 AGCs results were observed.

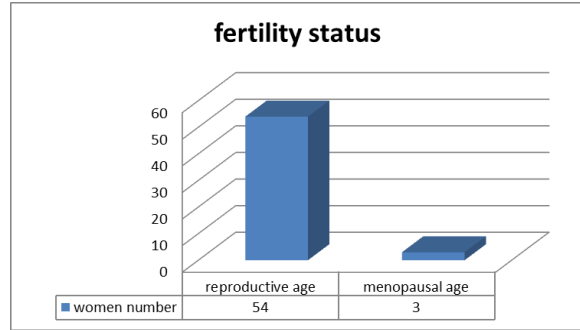


Figure 2 Lower incidence in menopausal women could be influenced by lower addressability to screening in this age group

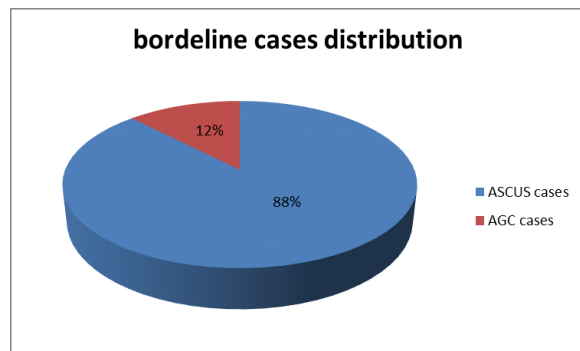


Figure 3 ASC-US is the most common cytological abnormality (88%), with lower incidence of AGC results (12%)

For ASCUS Pap smears with reflex HPV-DNA testing, we obtained 37 positive results.

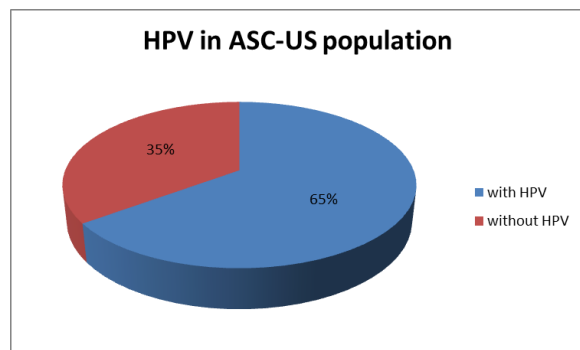


Figure 4 65% of ASC-US results were positive for HPV

Within HPV infected women, high risk HPVs, 16 and 18, which can cause cancer, were identified in 7 cases, low risk HPVs, which do not cause cancer but can cause skin warts, in 23 cases. Seven cases were positive for both low and high-risk HPV-DNA (but not 16 and 18 HR HPV).

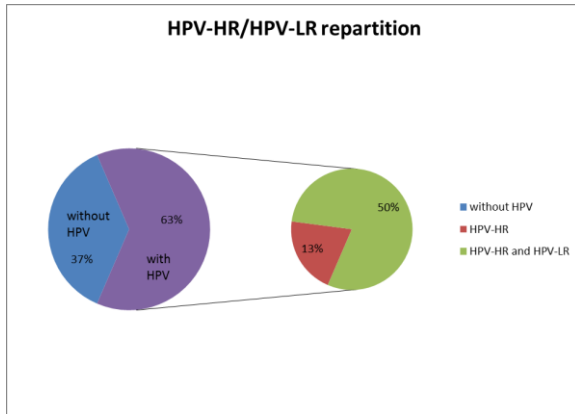


Figure 5 Among HPV infected women we discovered a higher incidence of simultaneous HPV-HR and HPV-LR infection

HPV-HR type 18 was identified in 2 cases, type 31 in 2 cases, and type 33 in 3 cases. Among 23 cases of low-risk HPV we found types 42, 62, 84 more often. We had 3 cases with perineal and vaginal warts at presentation. In two of these cases we found out coexistence of low-risk and high-risk HPV-DNA, and in one case only low-risk HPV-DNA. All 3 cases had HPV-DNA type 6. We perform colposcopy in all women. All 7 cases of ASC-US and HPV-HR 16, 18 associated abnormal colposcopic findings: high intensity of acetowhitening, vascular features as mosaic and punctuation and color changes after iodine application. In these cases we used molecular markers p16 and Ki67 for the diagnosis and for the transforming potential of low cervical intraepithelial neoplasia, and we obtain positive results in 5 cases.

HPV-LR and HPV-HR (other than 16, 18) and all AGC results associated normal or low-grade colposcopic findings. For ASC-US population we identify as additional risk factors: untreated long term bacterial vaginosis, multiple sexual partners and multiple curettages.

The incidence of atypical glandular cells of undetermined significance on Papanicolaou smears was low.

Women with abnormal vaginal bleeding were more likely to have a glandular lesion. In 7 cases with both endocervical and endometrial biopsy we found out 1 case of benign endometrial polyps, 1 case of typical endometrial hyperplasia and 5 normal results. Obesity, dysfunctional uterine bleeding, fibromas and ultrasound endometrial thickness above 15 mm were observed. After smear review at 6 months in 43 women, 36 smears were reclassified as negative in keeping with inflammation and atrophy, 3 were considered unsatisfactory, and 1 was upgraded.

In a study, Castle et al. were able to stratify the absolute risk for progression to CIN of grade 3 or higher in women with ASCUS cytology, based upon the type of HR HPV detected at the baseline screening⁷. High risk HPV prevalence decreases with age but risk of persistent infection increases with age. Postmenopausal women were more likely to have an ASCUS lesion.

CONCLUSIONS

Reflex HPV testing had a high sensitivity for detecting progression of lesion. All HPV 16 cases were associated with progressive lesion potential. We appreciate that it will remain prudent to continue to screen for ASCUS cytology cases every 6 months, especially when associated with HPV-HR or minor colposcopic changes. AGC results on patients with abnormal clinical presentations are predicting endometrial pathology, and should be followed closely.

Acknowledgement This work was co financed from the European Social Fund through Sectoral Operational Programme - Human Resources Development 2007-2013, project number POSDRU/1871.5/S/155631, entitled "Doctoral programs at the forefront of research excellence in priority domains: health, materials, products and innovative processes", Beneficiary - "Carol Davila" University of Medicine and Pharmacy Bucharest

REFERENCES

1. Evans, M., Adamson C., Papillo J.L.. Distribution of human papillomavirus types in thinprep Papanicolaou tests classified according to the Bethesda 2001 terminology and correlations with patient age and biopsy outcomes. 2006, *Cancer*,12:35,1054-1064
2. Apgar B. , Brotzman G. , Mark Spitzer.2008.Colposcopy: Principles and Practice.189-231
3. Apgar B.,Brotzman G.,Spitzer M.,Ignatavicius D.2002.Colposcopy: Principles and Practice: An Integrated Textbook and Atlas. 283-311
4. Mayeux E.J, Thomas Cox J.2011.Modern Colposcopy Textbook and Atlas.330:478
5. American Society for Colposcopy and Cervical Pathology. *Journal of Lower Genital Tract Disease*; 2012, 50:65
6. Wilkinson E.J .2012.Wilkinson and Stone Atlas of Vulvar Disease. 67:108
7. Castle P. E., Solomon D, Schiffman M, Wheeler CM. Human papillomavirus type 16 infections and 2-year absolute risk of cervical precancer in women with equivocal or mild cytologic abnormalities. 2005, *J. Natl Cancer Inst.* 97(14), 1066-1071