

ROSACEA AND HOMEOPATHY

Lawrence Chukundi NWABUDIKE

¹ National Institute of Diabetes, Nutrition and Metabolic Diseases “N.C. Paulescu”, Bucharest
Corresponding author: L.C. Nwabudike, E-mail: Chukwudi.nwabudike@live.com

Received July 2, 2012

Rosacea is a common cutaneous disorder affecting the face. It is more frequently encountered in fair-skinned races and in females. The aetiology is unknown. The treatment of rosacea can be difficult and includes topical treatments like benzoyl peroxide, clindamycin and metronidazole as well as systemic treatments like retinoids. We present three cases of rosacea treated homeopathically. They all had the papulopustular variant of rosacea. They comprised one male patient and two female patients. The treatments were individualized and included the homeopathic medicines Lachesis for the male patient and Causticum as well as Lycopodium for the female patients. Remission was seen in all three cases and was maintained after cessation of treatment. In conclusion, the cases show that homeopathy may be another alternative to the care of patients with this common, but difficult to treat disorder.

Key words: Rosacea, homeopathy.

INTRODUCTION

Rosacea is a common cutaneous disorder affecting mostly the face. It is characterized by erythema of the central face. Other features such as telangiectasis and papulopustular eruptions are common, but not universally present or required for a diagnosis¹. Currently, it is classified as erythematotelangiectatic (characterized by facial flushing and persistent erythema), papulopustular (characterized by persistent facial erythema as well as transient papules and pustules), phymatous (thickening of skin, irregular nodules affecting the nose, cheeks, forehead, chin or ears) and ocular (foreign body sensation in the eyes, itching, stinging, dryness as well as telangiectasis of the sclera)². A granulomatous variant comprised of noninflammatory, hard, yellow, brown or red papules or nodules of uniform size has also been described². This is not considered a subtype, but rather a variant of rosacea.

Epidemiology

This is a disorder more commonly encountered in fair-skinned races than in dark-skinned races. A

Swedish study, presumably on skin types I-II, gave a 10% prevalence³. On the other hand, a Tunisian study, in which the population had skin types IV-V, showed a prevalence of 0.2%⁴. Both studies indicated that it was a commoner disorder in women – F:M ratio of 2.5-3:1 in the studies mentioned^{3,4}.

Aetiology and pathogenesis

It is a disorder of uncertain etiology that is produced by trigger factors such as sunlight exposure, spicy foods, alcohol and emotions¹. Menopausal and drug-induced flushing also occurs. Rosacea is associated with the mite *Demodex folliculorum*, especially in the papulopustular (PPR) variety. The inflammatory reaction is thought to be triggered by the mites breaching the epithelial barrier of the hair follicle. A British study indicated that the PPR variety showed significantly higher levels of *D. folliculorum*, though not in the HIV associated cases of rosacea⁵⁻⁶. Other workers also noted increased mite populations in patients with PPR, but their attempt to use mite density as a diagnostic measure, at least for PPR, was unsuccessful⁷. Thus, the parasite may be an important

factor in the pathogenesis of this disease, but its exact role is not yet well elucidated.

RESULTS

Case presentations

Case 1

A 53 year-old retiree presented with a one-year history of facial eruption. The eruption began in the area between the eyebrows and spread to the cheeks. It was associated with itching and stinging sensations, made worse by shaving.

His past medical history was significant for a lumbar disc pathology and blindness in the right eye following an accident.

He had stopped smoking 4 years earlier and had smoked for 34 years, between 20-60/day. He also consumed home-made wine regularly.

Physical examination showed a middle-aged male in good health, with central facial erythema, papules and telangiectasis, mostly on the "butterfly area" of the face. There was a slightly left predominance to the eruption (Fig. 1).

He received the homeopathic medicine *Lachesis*, at M potency on a weekly basis for 6 weeks as well as Aloe vera cream, as needed.

He was seen 3 months later and already the symptoms were gone and the lesions much ameliorated (Fig. 2). He had also since stopped using the remedy. At 6 months after cessation of the use of the homeopathic medicine, the patient remained in remission (Fig. 3).

Case 2

A 32 year-old female presented with a 10-year history of facial rash previously diagnosed as seborrheic dermatitis. It was aggravated by sun exposure, cold weather, dust and anger. She had received a topical steroid (dermovate) cream for this, with only transitory effect. Her past medical history included a hand dermatitis that had also been unsuccessfully treated with allopathic and homeopathic agents.

She smoked about 10 cigarettes/day, for the past 11 years.

On examination, a young female in good general health, with erythematous plaques and pustules in the butterfly and zygomatic areas, especially on the right side was seen (Figs. 4A,B). She had no visible hand lesions.

She received the homeopathic medicine *Lycopodium*, at M potency, to be administered weekly and was asked to use Aloe vera cream as needed. At her 6-week follow-up visit, the lesions were healed (Figs. 4C,D). She continues to remain in remission. Her hand dermatitis also has improved.

Case 3

A 34-year old woman presented with a facial eruption of sudden onset, associated with occasional itching. She also felt stinging and redness with sun exposure.

She had been prescribed courses of systemic antihistamines and hydroxychloroquine tablets.

Her past medical history was insignificant.

On examination, she was found to have a papular, erythematous eruption, with mild underlying edema (Fig. 5).

She received the homeopathic medicine *Causticum*, at M potency on a weekly basis for 6 weeks. At 6 weeks, she had shown improvement with almost complete clearing of the lesions (Fig. 6). 8 months after cessation of treatment, she remains in remission.

DISCUSSION

Rosacea is a chronic disease of varying severity. It can be difficult to treat, especially where there is underlying edema.

The treatment of rosacea includes topical agents like benzoyl peroxide, clindamycin and metronidazole as well as systemic medicines like retinoids, metronidazole and doxycycline^{1,10}. Some of these therapies target the underlying inflammation seen in rosacea such as the macrolides erythromycin and azithromycin^{8,9}.

This may be due to the ability of this class of drugs to inhibit neutrophil chemotaxis and degranulation as well as cytokine production⁸. Lifestyle changes include the avoidance of trigger factors such as stress, spices and sun exposure¹¹. Laser therapy may also be effective¹¹.

The use of natural therapies in for the treatment of patients is not new and is on the increase¹².

Homeopathy is a safe, natural system of therapy first founded by the German physician Samuel Christian Hahnemann (1755-1843)¹³. He began the search for an alternative, safe, mild kind of treatment, as an alternative to the treatments given in his day, such as bleeding and purging, which benefits to the patients he could not see.

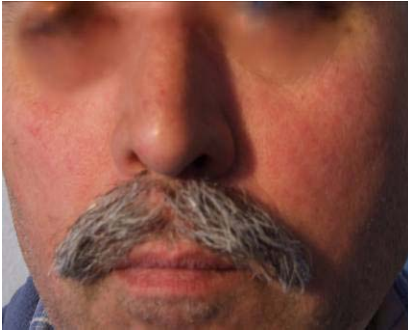

Fig. 1. Case 1 before treatment.

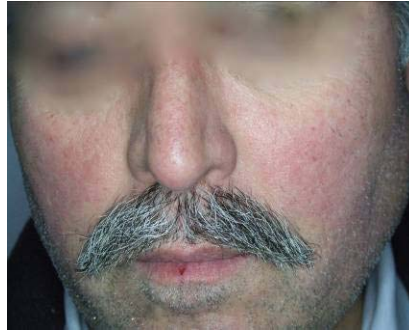

Fig. 2. Case 1 at 6 months after treatment.

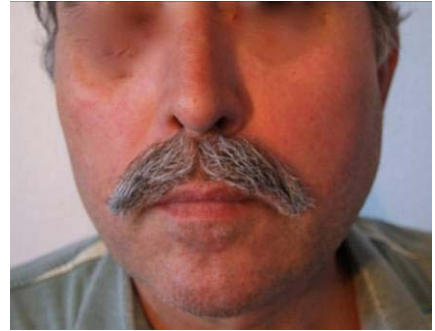

Fig. 3. Case 1 after treatment.

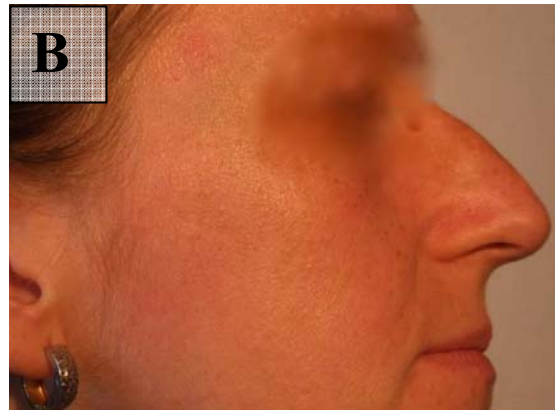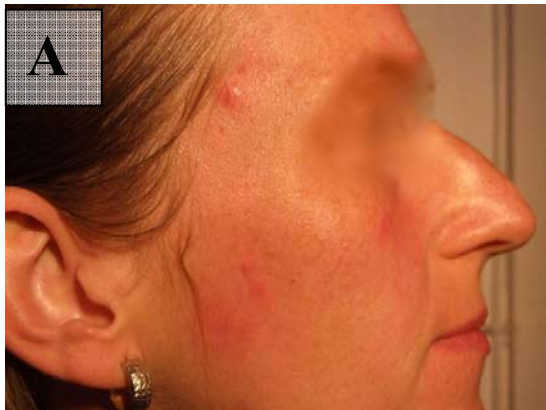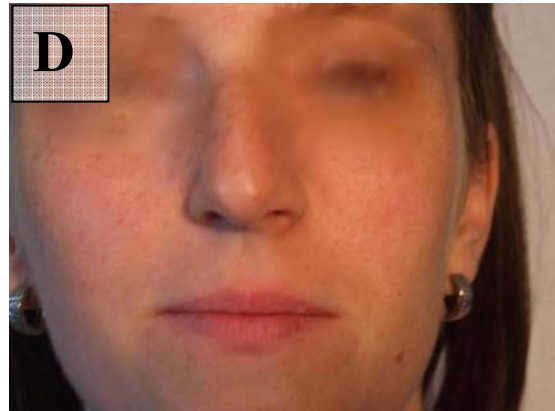
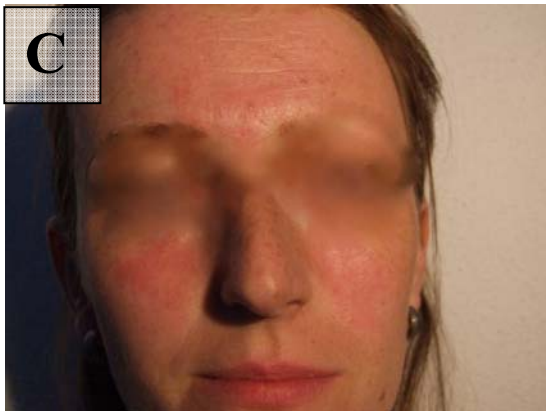


Fig. 4. A) Case 2 right profile before treatment, B) Case 2 right profile after treatment, C) Case 2 before treatment full face, D) Case 2 full face after treatment.

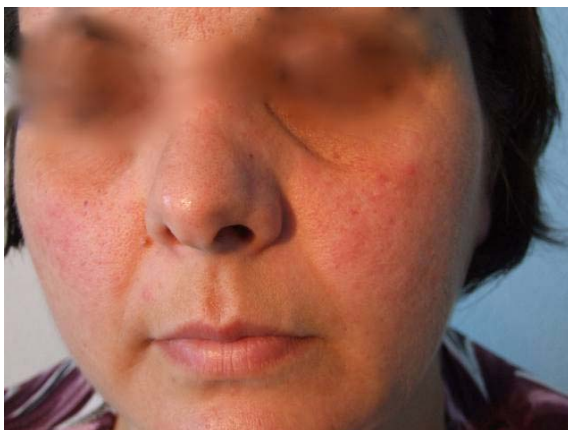

Fig. 5. Case 3 before treatment.

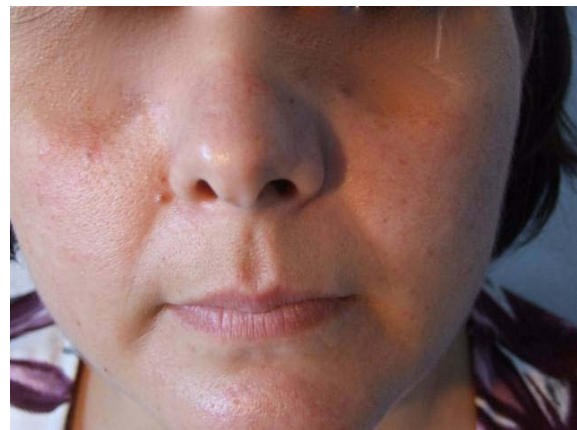

Fig. 6. Case 3 after treatment.

Homeopathy is based on the principle of similars, which states that a substance that may cause certain symptoms can alleviate those same symptoms at a lower dose. This principle was already elaborated centuries earlier by Hippocrates.

Homeopaths consider that the best therapies are individualized, hence several people (3 patients in this paper) with the same physical diagnosis may receive three different homeopathic treatments.

The dilution of homeopathic medicines often results in products in which, based on the Avogadro number, cannot have within them molecules of the medicinal substance. This, as well as the assertion of homeopaths that the greater the dilution, the greater the effect, have always been a cause of skepticism amongst non-practitioners of homeopathy.

It would appear that the question of whether such high dilutions can actually still be medicinally active has been answered by the work of the Nobel laureate Professor Luc Montagner. He was able to demonstrate that filtered solutions of bacteria still nonetheless gave out electromagnetic signals in the filtered solute. It would appear that the solute was able to generate nanoparticles in the solvent via a resonance phenomenon and that these nanoparticles generated electromagnetic signals identical to those of the original solvent¹⁴. Another work, using transmission electron microscopy and emission spectroscopy, would suggest that high dilutions of homeopathic substance would retain nanoparticles of the original substance¹⁵. This would defy the Avogadro number. Yet these nanoparticles could then conceivably continue to exert an effect. It may be, that, as indicated by the Luc Montagner group, that the original substance in the highly diluted homeopathic medicines may have generated a resonance phenomenon, which has been detected as nanoparticles. The authors speculated that a reason for the formation of these nanoparticles could be due to the process of violent shaking and banging against a hard surface, known as succussion, to which the solution is subjected during the dilution process¹⁵.

This has often raised the question in homeopathic circles and in the wider scientific world of whether there is a memory of water. This water memory may retain the energy signature of the solutes diluted in it.

Since homeopathic medicines are classically allowed to dissolve in the mouth, in order, by diffusion, to reach the blood stream, it may be speculated that the signals given off by the

nanoparticles are propagated throughout the bloodstream and the body, which are both overwhelmingly comprised of water. These signals may then trigger changes in body chemistry and physiology, which may lead to improved health. This could offer a putative explanation for how such high dilutions may actually have an effect.

As stated earlier, homeopathy is based on the principle of similars. This implies that the individual's unique constitution is a strong factor in determining the type of treatment to be administered, rather than the specific physical pathology. So, as in this paper, three patients with PPR received three different homeopathic medicines and all improved clinically.

Larger studies seem to indicate that homeopathy may be effective in the management of atopic dermatitis, especially in a clinical, everyday setting^{16,17}.

The cases of rosacea presented were of the papulopustular variety, with telangiectasis being prominent in case 1 and erythema in case 2.

Case reports indicate that homeopathy has been found to also be useful in the treatment of, chronic eczema¹⁸, lichen striatus¹⁹, verucca vulgaris²⁰, psoriasis²¹, seborrheic dermatitis²², acne²³ and melasma²⁴. We also published a case series of patients with atopic dermatitis that are already in long-term remission²⁵. The patients in the studies cited above have remained in remission after the cessation of treatment.

CONCLUSIONS AND FUTURE PROSPECTS

Homeopathy is a cheap, naturopathic form of treatment, which is very safe and easy to use. The experience described in this paper, as well as the those of other workers cited here also make the case that it may be a useful alternative to treatment of patients suffering from rosacea and other dermatoses, even in cases that are refractory to conventional therapy. A possible mechanism of action is by the effect of nanoparticles, formed by resonance phenomena, which stimulate the body's energy to bring about improved health. How exactly the nanoparticles do this is still to be elucidated. Treatment costs, barring consultations, were in the range of 2-3 Euro/case, which is much less than the costs incurred by patients on conventional therapy, with the added advantage of low, almost nonexistent risk of side-effects.

Further and continued investigation, as well as larger studies, would be required to determine the role that homeopathy may have to play in the management of skin diseases. Judging by the case reports presented in this paper, homeopathy is a treatment modality warranting serious consideration and it is hoped that this paper will help to stimulate wider studies in this direction.

REFERENCES

- Pelle MT. Rosacea [in] Fitzpatrick's Dermatology in General Medicine. Wolff K, Goldsmith LA, Katz SI, Gilchrest BA, Paller AS, Leffel DJ, McGraw Hill Publishers, 2008
- Wilkin J, Dahl M, Detmar M, Drake L, Feinstein A, Odom R, Powell F. Standard classification of rosacea: Report of the National Rosacea Society Expert Committee on the Classification and Staging of Rosacea. *J Am. Acad Dermatol.* 2002;46:584-587.
- Berg M, Liden S. An epidemiological study of rosacea. *Acta Derm. Venereol.* 1989;69(5):419-423.
- Khaled A, Hammami H, Zegloui F, *et. al.*, Rosacea: 244 Tunisian cases. *Tunis Med.* 2010;88(8):597-601.
- Forton F, Seys B. Density of Demodex folliculorum in rosacea: a cas-controlled study using standardized skin biopsy techniques. *Br. J. Dermatol.* 1993; 128(6):650-9
- Forton FM. Papulopustular rosacea, skin immunity and Demodex: pityriasis folliculorum as a missing link. *J Eur Acad Dermatol Venerol.* 2012; 26(1):19-28.
- Erbağci Z, Ozgötaşı O. The significance of Demodex folliculorum density in Rosacea. *Int. J Dermatol.* 1998; 37(6):421-5.
- Labro MT. Anti-inflammatory properties of macrolides: a new therapeutic potential? *J Antimicrob Chemother.* 1998;41(Suppl. B): 37-46.
- Alzolibani AA, Zedan K. Macrolides in Chronic Inflammatory Skin Disorders. *Mediators Inflamm* 2012; doi:10.1155/2012/159354.
- Korting HC, Schöllman C. Current topical and systemic approaches to treatment of rosacea. *JEADV* 2009;23:876-882.
- Odom R, Dahl M, Dover J, Draelos Z, Drake L, Macsai M, Powell F, Thiboutot D, Webster GF, Wilkin J. Rosacea, Part 2: Standard management options according to subtype. *Cutis* 2009;84: 97-104.
- Eisenberg DM, Davis RB, Ettner SL, Appel S, Wilkey S, van Rompay M, Kessler RC. Trends in Alternative Medicine Use in the United States, 1990-1997. Results of a follow-up national survey. *JAMA* 1998;280(18):1569-1575.
- Hahnemann SC. *Die chronische Krankheiten: theoretische Grundlagen.* Karl F. Haug Verlag, 2001
- Montagner L, Aïssa J, Ferris S, Montagner J-L, Lavallée C. Electromagnetic signals are produced by aqueous nanostructures derived from bacterial DNA sequences. *Interdiscip Sci Comput Life Sci.* 2009; 1:81-90.
- Chickramane PS, Suresh AK, Bellare RJ, Kane GS. Extreme homeopathic dilutions retain starting materials: A nanoparticulate perspective. *Homeopathy* 2010; 99:231-242.
- Itamura R, Hosoya R. Homeopathic treatment of Japanese Patients with Intractable Atopic Dermatitis. *Homeopathy* 2003; 92:108-114.
- Witt CM, Lüdke R, Willich SN. Homeopathic treatment of children with atopic eczema: a prospective observational study with two years follow-up. *Acta Dermato-Venerologica* 2009; 89:182-183.
- Signore RJ. Classic homeopathic medicine and the treatment of eczema. *Cosm Derm* 2011;24:420-425.
- Signore RJ. Treatment of lichen striatus with homeopathic calcium carbonate. *Jl. Amer Ost College of Derm* 2011;21(1):43.
- Nwabudike LC Homeopathy in the treatment of verruca vulgaris – an experience of two cases. *Proc. Rom. Acad., Series B,* 2010; 2:147-149.
- Nwabudike LC. Psoriasis and Homeopathy, *Proc. Rom. Acad., Series B.* 2011, 3, p 237-242
- Nwabudike LC Seborrheic dermatitis and homeopathy. *Our Dermatol Online.* 2011, 2(4):208-210 (www.odermatol.com)
- Nwabudike LC, Acnee si tratamentul ei homeopat (The homeopathic treatment of acnee), Romanian congress of dermatology, 2010
- Nwabudike LC. Melasma and Homeopathy. *Homeopathic Links* 2012; 25:99-101.
- Nwabudike LC. Atopic dermatitis and homeopathy. *Our Dermatol Online.* 2012; 3(3):217-220 (www.odermatol.com).